

Original article

Traumatic Brain Injury: CT Imaging, Management and Epidemiology of 850 cases from tribal tertiary care centre in Maharashtra

Dr Shakuntala Limbaji Shelke¹ Dr Ajay Dnyanoba Subhedar² , Dr Mukesh Suresh Bava³

¹Associate Professor Radiology, SBHGovt.Medical college, Dhule. Maharashtra.

²Associate Professor Surgery, SBH Govt. Medical college Dhule ,Maharashtra.

³Assistant Professor community Medicine, Govt. Medical college dhule, Maharashtra.

Corresponding author: Dr Ajay Dnyanoba subhedar , Associate Professor Surgery, SBH Govt. Medical college Dhule ,Maharashtra.

Abstract:

Background: Traumatic brain injury(TBI) is a form of acquired brain injury resulting from an external mechanical force leading to temporary or permanent impairment of cognitive, physical and psychological functions with associated diminished or altered state of consciousness. It is recognized as a major public health problem that is a frequent causes of death and disability in young people and makes considerable demands on health services.. In this new era of radiology, computed tomography has become the primary modality of choice in the initial assessment of head injury patients as it is widely available, faster and highly accurate in detecting skull fractures and acute intracranial hemorrhage. Epidemiological data are required to initiate appropriate preventive measures and to plan necessary services

Aims and objectives: To study the demography of the traumatic brain injury cases, to find out causes of it, to study imaging and outcome of TBI & suggest the recommendation based on the study.

Materials and methods:Present study is carried out at SBH Govt. medical College, Dhule during the period of a calendar year,1st January 2015 to 31st December 2015. CT scan of the patients were studied for the presence of intracranial hemorrhage,contusion and various other abnormalities.Epidemiology and clinical outcome of patients was evaluated.

Statistical analysis: A descriptive analysis of the collected variables to understand the age-group, cause of injury, and imaging findings among patients. We also described the outcome with respect to the Glasgow coma scale on admission. Appropriate tests of significance were used

Results: Out of 850 patients CT scan was indicated in 692 cases.We noted significant CT findings in 428 (61.84%) cases and it was normal in 264 (38.15%) cases. Other finding were diffuse and localized edema (47.54%), depressed fracture (9.68%), Sub arachnoid hemorrhage (7.5%), EDH (5.34%), SDH (5.05%). Midline shift due to edema and hematomas were present in 13.29% cases.

Conclusions:Traumatic brain injury predominantly affects young male population. CT scanning is the primary modality of choice in the diagnostic work up. CT scan can detect and precisely localize the parenchymal damage of brain. These CT findings can be used as prognostic indicators and useful during counseling of relatives of patients.

Keywords: Brain edema, Computed tomography, Diffuse axonal injury, Epidemiology, Intracranial hemorrhage, Rural, Traumatic brain injury.

INTRDOUCTION:

Trauma is one of the leading causes of death and disability in Indian population¹Traumatic brain injury (TBI) is one of the most devastating types of injury. It affects all ages; however majority of road traffic injuries (RTI) occurs in young adults of productive age group. As per report by the ministry of road transport, Government of India (2007) 1.4 lakhs road accident happened in 2007 with 40,612 people killed and 1.5 lakhs people injured.² TBI is also associated with significant socioeconomic losses in India as well as in other developing countries.³Worldwide it is a major public health problem and is predicted to surpass many diseases as a major cause of death and disability by the year 2020. The majority (60%) cases are due to road traffic injuries (RTI), followed by falls (20-25%) and violence (10%).⁴ Each year 1.4 million people in the UK suffer head injury (Menon 1999)⁵. Recovery from severe injuries can take years, and might never be complete; only half of those patients with serious head injury return to work (Flint 1999).⁶ Head injury is most likely to happen to young men, with an average age of 30, who are involved in road traffic accidents (RTAs) (Allen and Ward 1998)⁷.

The rapid motorization of India, especially during the past two decades, has resulted in increasing numbers of injuries and deaths due to road traffic crashes⁸. The significant disabilities associated with TBI also places a considerable burden on health care system in these countries, therefore knowledge of the epidemiological profile of TBI and development of preventive measures to alleviate this burden are vital, particularly in the limited resources setting⁹. Young males are commonly affected population in TBI.¹⁰ Most common clinical presentation in TBI

patient is headache and vomiting followed by skull fracture with history of loss of consciousness. Neurological assessment for assessing severity of TBI is commonly done by Glasgow coma scale (GCS) but low score of GCS do not necessarily predict bad outcome.¹¹The diagnosis and management of head trauma have been changed significantly with the wide availability of CT scan since its inception in 1970s.¹²Computed tomography (CT) has become the diagnostic modality of choice for head trauma due to its accuracy, reliability, safety, and wide availability. The changes in microcirculation, impaired auto-regulation, cerebral edema, and axonal injury start as soon as head injury occurs and manifest as clinical, biochemical, and radiological changes. Proper therapeutic management of brain injury is based on correct diagnosis and appreciation of the temporal course of the disease process.¹³Cases of head injury with fracture tend to have more complications and are more often fatal than those without fracture. However, a normal CT scan does not mean that everything is alright as the patient may be suffering from diffuse axonal injury.¹⁴

RESULTS:

Demographic characteristics of Head injury cases-

Out of 850 cases, males and females were 88.58% and 11.42% respectively. It shows the number of male victims more than the females. The maximum number of head injury cases were in younger age group i.e. 21-30 years i.e. 42.70%. In 0-10 years of the age group the head injury was 1.76% while more than 60 years age were 2.35%. In 11-20 years of age group, the head injuries were 18.23% while 12.30% were in 31-40 years of age group (Table 1). The frequency of Head injury was more (64.81%) in the rural areas than urban areas (35.19%).

AGE IN YEARS	MALE	FEMALE	TOTAL
0-10	14 (93.33%)	1 (6.66%)	15 (1.76%)
11-20	143 (92.26%)	12 (7.74%)	155 (18.23%)
21-30	312 (85.91%)	51 (14.09%)	363 (42.70%)
31-40	144 (87.80%)	20 (12.20%)	164 (12.30%)
41-50	39 (86.67%)	6 (13.33%)	45 (5.39%)
51-60	83 (94.31%)	5 (5.68%)	88 (10.35%)
60	18 (90.00%)	2 (10.00%)	20 (2.35%)
Total	753 (88.58%)	97 (11.42%)	850 (100%)

Table-1: Age and sexwise distribution of head injury cases

Time period of accidents;It was observed that incidence of Head injuries were maximum within 12 Noon-6 PM (45.31), followed by 6AM – 12 Noon i.e.

23.41% and 6 PM-12 Midnight 24.70%. The daytime head injuries were more than night time injuries. (Table 2)

Sr. No.	Clockwise	No. of cases
1	12 Midnight-6 AM	56 (6.58%)
2	6 AM-12 Noon	199 (23.41%)
3	12 Noon – 6 PM	385 (45.31%)
4	6 PM – 12 Midnight	210 (24.70%)
Total		850 (100%)

Table-2: shows the time of accident

Causes of accidents: The Type of vehicles involved in accidents causing head injury in study cases were two vehicle accident in 42.33% and bicycle riders 4.94%. The pedestrian contribute 12.33% of the head injury. 5.30% were fall in home or outside, 0.82%

bullock cart accident, 10.23% in four vehicles and 22.33% in homicidal injury. (Fig 1). Out of 850 head injury cases 9.42% were alcoholic while 90.58% were non alcoholic at the time admission.

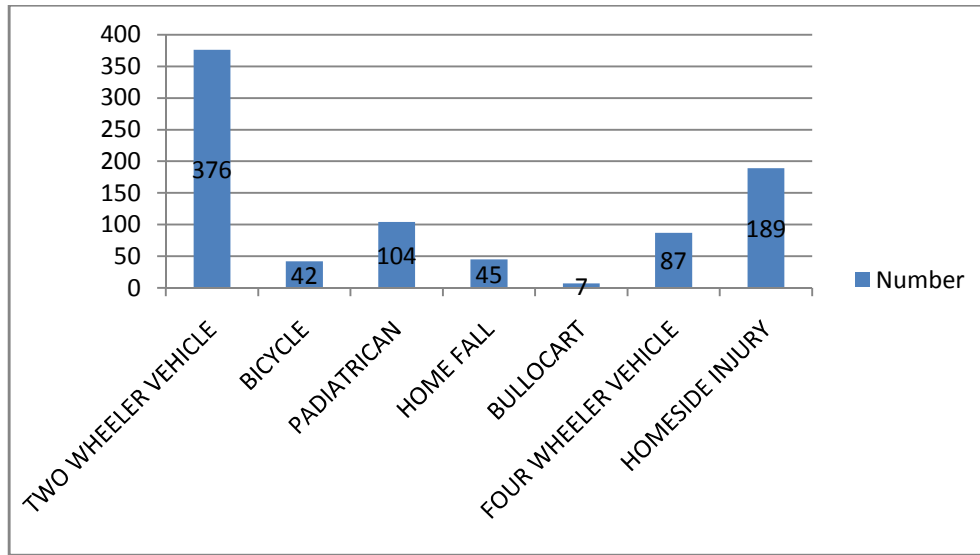


Fig 1 showing the vehicle involved in accidents causing of head injury

Management & outcome of head injury cases

Glasgow coma scale was noted on paper which was categorized into 3, 4-8, 9-11 and 12-15. 5.76% of the head injury cases were having Glasgow coma scale 3.

In the 20.72% of the head injury cases, the scale was between 9-11 while 61.41 percent in between 12-15. (Table 3)

Glasgow coma scale	Percentage
3	49 (5.76%)
4-8	103 (12.11%)
9-11	176 (20.72%)
12-15	522 (61.41%)
Total cases	850 (100%)

Table-3:shows the Glasgow coma scale in head injury cases

Computed tomography imaging was done in 692 patients. Majority,428 patients showed significant CT findings. In most of the cases it showed more than one finding. Depending on the most prominent finding, CT images were grouped as-

No	CT Finding	No of cases
1	Normal CT scan	264(38.15%)
2.	Linear fracture skull	187(27.02%)
3.	Depressed fracture skull	67(9.68%)
4.	Diffuse and localized edema	329(47.54%)
5.	Epidural hematoma	37(5.34%)
6.	Subdural hematoma	35(5.05%)
7.	Subarachnoid hemorrhage	52(7.51%)
8.	Midline shift	92(13.29%)
9.	Difuse axonal injury	24(3.36%)

Table No-4: CT findings in our study

The various operative procedures were indicated to save the patient life. 147 patients were referred for neurosurgery. Tracheostomy was indicated in 159 cases. We did wound toilet and CLW suturing 589 cases. Apart from head injury, many cases were having injuries to chest, abdomen and soft tissues as well. For these we didexploratory laprotomy in 72

cases, intercostals tube drainage in 104 cases, surgery for bone fractures in 255 cases and 27 dental procedures (Table 5). Causes of death was noted in the patient in the study case. Out of total deaths, in 80.15% of deaths head injury was a single causes of death. 12.70% deaths were due to injury to the vital organs while 7.15% due to polytrauma.

Operative procedure	Numbers
Neurosurgery indicated	147
Tracheostomy	159
Elevation of fracture	22
Wound toilet and CLW suturing	589
Exploratory laprotomy	72
Intercostals tube drainage	104
Surgery for bone fractures	225
Dental procedures	27

Table-5:operative procedures of our study

DISCUSSION:

Involvement of maximum number of males in head injury cases is due to the nature of works exposing the males in outdoor activity. The mobility of male population is higher than their female counterpart and they are exposed to more accidental risk factors at various places¹. Similar results were reported by WHO (1976)¹⁵; in the States of USA, Tyagi A.K. et al (1986)¹⁶, Salgado M.S.L. et al (1988)¹⁷, Kumar A et al (1999)¹⁸, Vikrant Ket al (2016)¹⁹, Yattoo G.H. et al (2004)¹⁰, Gupta P.K. et al (2011)¹³, Tomar S.S. et al (2013)¹² and Bhole A.M. (2007)¹⁴. Regarding the age of RTA victims, 21-30 years age group showed almost 1/3rd of total cases and if we considered age group 21-40 years it showed more than half of total victims. Similar findings were reported by Kumar A et al (1999)¹⁸, Chandra J (1979)²⁰, and Pillay V.V. (1992)²¹. Considering the types of vehicle involved in, 42.23% of the head injury noted in two wheeler vehicle while 10.23% were in four wheeler vehicle. It reveals the more use of 2-wheeler vehicle by untrained persons. While these findings are different by Voret F (1993)²² in their studies this might be due to geographic distribution and locality of the study.

It is also observed that incidents were more in rural areas (64.81%) than urban or semi-urban areas (35.19%). Gabella B, et al²³ used a State Surveillance System to identify cases of traumatic brain injury. The study showed higher rates of severe traumatic brain injury in rural as compared to urban areas. Yattoo GH et al¹⁰ also showed higher rates of traumatic brain injuries in rural (71.1%) than urban (28.9%) areas. In spite of best management, 15-20% of head injuries prove fatal²⁴. Yattoo GH et al¹⁰ noted death in 6.4% patients. Deaths due to the head injury in our study were 14.82%. It reveals the need of more

Intensive Care Unit for Victims at Civil Hospital Level as well as Medical Colleges of this region.

Along with the head injury, other body injuries were also noted and treated in our hospital. Chest injury in 219 cases, 92 abdominal injuries, 132 long bone injury of upper extremity, 149 long bone injuries of lower extremity, 42 spinal injuries and 38 other injuries. The chest injury includes fracture ribs, multiple fracture ribs, flail chest then pneumothorax and hemopneumothorax also includes surgical emphysemas. For this many patients required blood transfusion and intercostals tube drainage with underwater seal. For abdominal injury 74 cases went for explorative laprotomy for hemoperitoneum, liver, spleen, intestinal and other vital organ injury. The bone injuries were managed by orthopedic department.

Chandra Shekharet al¹ noted abnormal findings on CT head in 67% of cases. Which includes brain contusion and subdural hematoma (SDH) in 26% cases, contusion and SDH in 15% cases, Skull fracture in 13% cases, brain contusion in 10% and pneumocephalus in 3% cases of TBI. In the study by Yattoo GH et al¹⁰ highest number of patients were having scalp lacerations (40.4%) followed by contusion (8.8%), EDH (3.2%), SDH (4.2%) and depressed fracture (3%). Our study findings correlate with these studies. We noted abnormal CT findings in 61.84% cases, normal in 38.15% cases, Diffuse and localized edema (47.54%), depressed fracture (9.68%), Sub arachnoid hemorrhage (7.5%), EDH (5.34%), SDH (5.05%). Midline shift due to edema and hematomas were present in 13.29% cases. Features on CT such as intraventricular hemorrhage, effacement of basal cisterns, midline shift, diffuse axonal injury and herniation are associated with unfavorable outcome.¹⁹ In Early

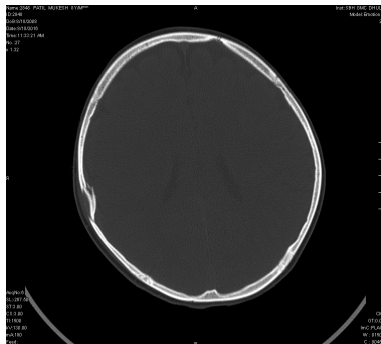
detection of Extradural Hematoma (EDH), Subdural hematoma (SDH) and depressed fracture will improve outcome of these patients by early surgical intervention.¹⁰ Several studies have reported the presence of subarachnoid hemorrhage in TBI as a powerful factor associated with poor outcome.¹⁹

Cranial Computed Tomography Scan

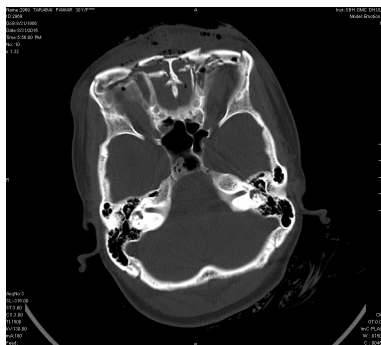
Most patients had multiple findings on CT scans, therefore, they were grouped on basis of the principal finding on CT images.

Fractures:

Depressed fractures of skull vault were considered to be present when at least one skull bone showed inward displacement, while linear fractures means no displacement of bone fragments²⁵. When the outer table of the skull was displaced below the level of the inner table, it was considered as depressed fracture. We found 187(27.02%) linear fractures and 67(9.68%) depressed fractures in our study.



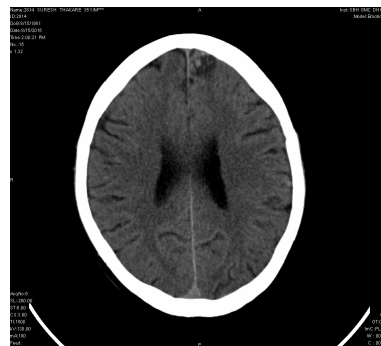Right parietal depressed fracture



bilateral frontal bone fractures.

Contusion:

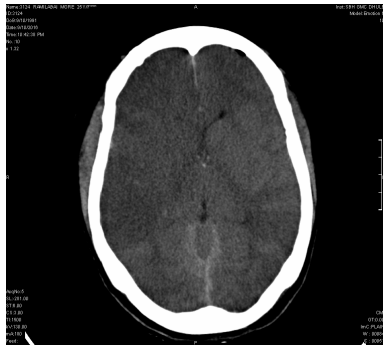The lesion was seen as areas of hemorrhagic necrosis with edema and appeared as areas of heterogeneous increased density. Brain contusions can be hemorrhagic and non hemorrhagic and they are commonly found in patients who sustained blunt head trauma and in acceleration and deceleration trauma where they present as coup or contre coup injuries²⁶. On plain CT, contusions appear as hypodense areas if hemorrhage is absent and hyperdense areas if hemorrhage is present.



left frontal contusion.

Brain Swelling and Edema:

Diffuse brain swelling occurs when there is loss of cerebral autoregulation which results in increase in blood flow and blood volume forcing CSF out of the ventricles and subarachnoid spaces, which causes compression of cistern spaces and ventricles which presents as mild increased density of white matter²⁶. Localised brain edema is seen as an ill-defined hypodense area with shift of the midline structures to the contralateral side which may be the only presenting feature.^{27,28} In our study diffuse and localized brain swelling was seen in 329 (47.54%) of the patients.



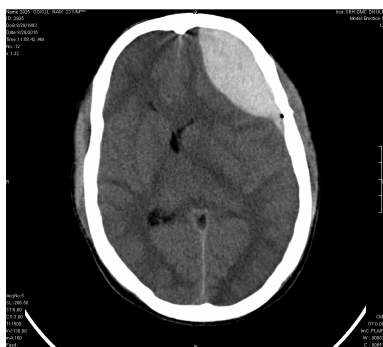diffuse brain edema

Intracerebral Hematoma:

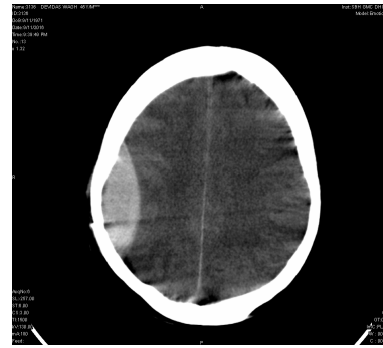
Intracerebral hematomas presented as homogeneously hyperdense, with sharp margins surrounded by a rim of decreased density. Considerable mass effect was present, depending on the size of the lesion .

Epidural Hematoma:

The radiological appearance of a typical epidural hematoma was biconvex, lentiform, biventricular, crescentic or irregular and was heterogeneous in attenuation, containing areas of hyperdense blood clot and isodense serum. Most commonly bleeding is from an injured middle meningeal artery, near to the inner table, from a fracture of the adjacent bony cranium with shift of ventricles^{28,29}. We found 37 cases (5.34%) of epidural haemorrhage.



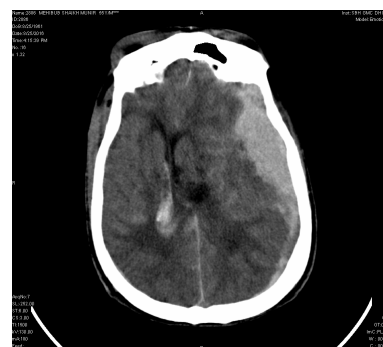left frontal extradural hematoma with right midline shift



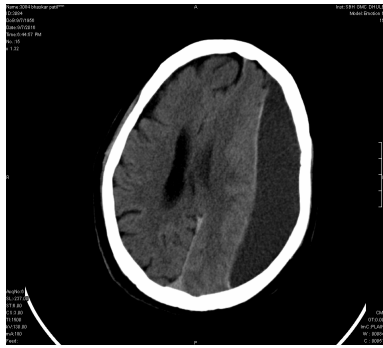right parietal extradural hematoma.

Subdural Hematoma:

The typical appearance was a hyperdense crescent-shaped extra-axial collection with a convex lateral border and concave medial border overlying the cerebral convexity. Mass effect with compression of adjacent cortical sulci and ventricles and effacement of adjacent cisterns, midline shift can be seen due to it. It can also present as iso or hyperdense area and can occur in interhemispheric fissure especially along postero-superior aspect in head trauma cases.^{30,31} Subdural hematoma was found in 35 (5.05%) of cases in our study. Tomar S.S.et al¹² noted acute SDH in 18% of the study cases other studies have shown 19%, 9%, 12.6%, 16% and 59%²⁹.



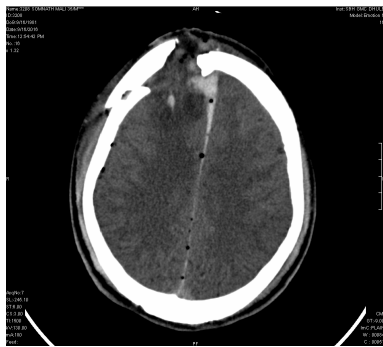left subdural hematoma with subarachnoid hemorrhage with midline shift



left subdural hematoma with right midline shift.

Subarachnoid Hematoma:

Subarachnoid hemorrhage is often seen adjacent to a contusion and occurs in children and elders who have large subarachnoid spaces. On CT scan, hyperdensity of acute hemorrhage was visualized in the sulci overlying the cerebral convexities, within the sylvain fissures, basal cisterns, and inter-hemispheric fissure. In our study 52 (7.5%) CT images showed subarachnoid hemorrhage.

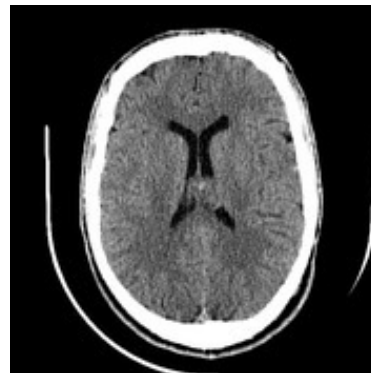


Right frontal bone fracture with subarachnoid hemorrhage with right frontal bone fracture.

Diffuse Axonal Injury:

Causes being acceleration, deceleration and rotational forces which result in portions of the brain with different densities to move relative to each other resulting in the deformation of axons and disruption of axoplasmic transport.³² Immediate loss of consciousness is typical of these injuries. Despite the patient's presentation with a profound neurological deficit, CT can be normal. Diffuse axonal injury is diffuse and bilateral, appears on CT as multiple foci

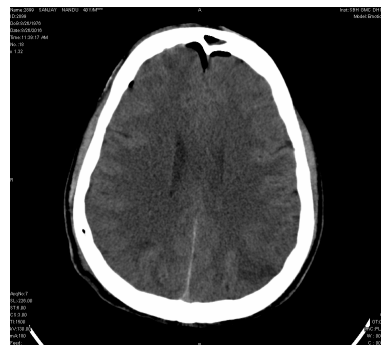of high attenuation of 5 - 15 mm involving the lobar white matter at the gray-white matter interface most commonly, corpus callosum, dorsal lateral upper brain stem, the basal ganglia or in the posterior limb of internal capsule however, others add brain swelling and intraventricular hematoma too^{27,28}. Diffuse axonal injury denotes a poor prognosis.^{30,31} CT is not sensitive in detecting it as most of the lesions are small and non hemorrhagic which can be missed.^{30,32}



diffuse axonal injury with thalamic and corpus callosum hemorrhage.

Pneumocephalus:

A pneumocephalus presents as areas of low attenuation on CT (air pockets) and can result from fracture of any air containing cavity like sinuses, mastoid bone and skull base.²⁹ In our study pneumocephalus was observed in 56 cases.



bilateral frontal pneumocephalus

CONCLUSION:

The study shows number of male victims more than the female. The maximum number of head injury in younger age group i.e.21-30 years. It was observed that incidence of Head injuries were maximum within 12 Noon-6 PM followed by 6AM-12 Noon and 6 PM-12 Midnight, the daytime head injuries were more than night time injuries. It shows that frequency of Head injury was more in the urban areas and rural areas.The causes of the head injury in study cases were two wheeler vehicle accident and bicycle riders. Maximum number of cases were non alcoholic at the

time of admission. Glasgow coma scale was noted on paper which was categorized into 3, 4-8, 9-11 and 12-15. 40% cases had it below 12.Total 692 patients underwent Computed Tomography imaging out of which 428 shown findings of moderate to severe cranio-cerebral injuries. Majority of them required further intensive care management.The other body injuries were also noted and treated in the hospital, most had chest injury followed by soft tissue injury.80.15% cases of the total deaths,head injury was a single cause of death.

RECOMMENDATIONS:

Traumatic brain injury continue to be growing menace, incurring heavy loss of valuable man-power and human resources, along with a corresponding drain of potential economic growth and hence, as a conclusion, we would like to suggest some recommendations which are listed below:

Specific recommendations

1. The Results of this study suggest the need for large prospective studies that would assist various organizations to set and plan preventive programmes.
2. Based on these observations, it is further recommended the need of separate ICU for management of complex life threatening conditions in an organized manner with provisions of intensive monitoring system and life sustaining therapies.
3. Committed and appropriate trained staff having knowledge of adequate skill and care of providing life-support and advanced life-support measures to the critically ill patients should be made available along with financial resources.
4. Computed Tomography facility and neurosurgery care must be available at every district hospitals for perfect diagnosis of the cases and early management.

General recommendations

Public awareness about road safety and maintenance of roads. Licensing authority should follow rules strictly. Regular check up of condition of vehicles and Medical examination of driver & alcohol breath test.

REFERENCES:

- 1.Chandra Shekhar, Gupta LN, Ishwar Chandra Premsagar et al.An epidemiological study of traumatic brain injury cases in a trauma centre of New Delhi(India).J Emerg Trauma Shock.2015 july-sep;8(3):131-139.
- 2.Samabasivan M. Epidemiology of Neurotrauma.Neurology and Prevention.Neurol India (Supl) 1991;43:9-15.
- 3.Ramamurthi B. Road accidents, Epidemiology and Prevention. Neurol India (Supl) 1991;43:9-15.

4. Gururaj G. Epidemiology of traumatic brain injuries: Indian scenario. *Neurol Res.* 2002;24:24-8. [PubMed]
5. Menon DK (1999) cerebral protection in severe brain injury: physiological determinants of outcome and their optimization. *British Medical Bulletin* 55, 1, 226-258.
6. Flint G (1999) Head injuries. *British Journal of Theatre Nursing.* 9,1, 15-21.
7. Allen CH, Ward JD (1998): An evidence-based approach to management of increased intracranial pressure. *Critical Care Clinics.* 14,3, 485-495.
8. Amit Agrawal, Sagar Galwankar, Vikas Kapil et al. Epidemiology and clinical characteristics of traumatic brain injuries in rural setting in Maharashtra, India. 2007-2009. *Int j Crit Illn Inj Sci.* 2012 Sep-dec;2(3):167-171.
9. Puvanachandra P, Hyder AA. The burden of traumatic brain injury in Asia: A call for Research. *Pak J Neurol Sci.* 2009;4:27-32.
10. Yattoo GH, Tabish A. The profile of Head injuries and traumatic brain injury deaths in Kashmir. *J Trauma manag Outcomes.* 2008;2:5 [PMC Free article] [Pub Med].
11. Waxman K, Sundine MJ, Young RF. Is early prediction of outcome in severe head injury possible? *Arch Surg.* 1991;126:1237-42. [PubMed]
12. Tomar SS, Anuj Bhargava, Nikitha Reddy. Significance of computed tomography scans in head injury. *Open Journal of Clinical Diagnostics,* 2013,3,109-114.
13. Gupta P K, Krishna Atul, Dwivedi Amit N et al. CT Scan Findings and Outcomes of Head Injury Patients: A Cross Sectional Study. *JPMS Volume 1, Issue 3 (October-December, 2011),* Pg,78-82.
14. Bhole AM, Patole R., Agrawal A. et al. Demographic profile, clinical presentation, management options in cranio-cerebral trauma: An experience of a rural hospital in central India. *Pak J Med Sci* 2007 Vol.23 No. 5,724-727.
15. WHO 'The Epidemiology of Road Traffic Accident' Report on a conference at Vienna 4th to 11th November, 1975, WHO regional publication European series No.2, 1976.
16. Tyagi AK, Sharma GK, Kumar B.: Cranio-cerebral damage by blunt force impact. *Journal of Indian Academy of Forensic Medicine.* 1986; 1: 24-39.
17. Salgado MSL & Colombage SM : Analysis of fatalities in road accidents. *Forensic Science International* 1988; 36: 91-96.
18. Kumar A, Qureshi GU, Aggarwal A and Pandey DR.: Profile of thoracic injuries with special reference to road traffic accidents in Agra, 'Journal of Indian Association of Forensic Medicine. 1999; 21 (4): 104-109.
19. Vikrant Kanagaraju, Arunkumar V.B, Devanand B. et al. Evaluation of CT Imaging Features In Predicting Clinical outcome in Moderate to Severe Traumatic Brain Injury. *IOSR Journal Of Dental and Medical Sciences (IOSR-JDMS)* e-ISSN:2279-0861. Volume 15, Issue 2 Ver. VIII (Feb.2016), PP108-113.
20. Chandra L, Dogra TD, Dikshit PC : Pattern of cranio-intracranial injuries in fatal road traffic accidents in Delhi. 1966-76. *Medical Science & Law* 1979; 19 (3) 186-94.
21. Pillay : Indian Academy of Forensic Medicine Scientific article of IJV Annual Conference 1992, Jan 4th III.
22. Vorel F : Traffic injuries in the pedestrians. *Journal of Czech-Slovak Forensic Medicine.* 1993; 38 (4): 32-36.
23. Gabella B, Hoffman RE, Marine WW: Head injury, in Year Book of Emergency Medicine. Edited by: Wagner DK, Dandson SJ, Dronen S, et al. 1999, Year Book of Emergency Medicine, 9-11.
24. Kirmani MA, Sexena RK, Wani MA: The spectrum of Head Injury in the Valley of Kashmir as seen at Sher-i-Kashmir Institute of Medical Sciences, Srinagar, Kashmir. Thesis submitted for M.S (General Surgery). 1986
25. Smits M, Hunik MGM, Von Rijssal DA, Dekkor HM, Vos PE, Kool DR et al. Outcome after complicated minor head injury. *AJNR Am J Neuroradiol* 2008;29:506-13.
26. Traumatic Brain Injury (1997) Colorado, Missouri, Oklahoma, and Utah, 1990-1993. *Morbidity and Mortality Weekly Report,* 46, 8-11.

27. Zee, C.S., Hovanessian, A., Go, J.L. and Kim, P.E. (2002) Imaging of sequelae of head trauma. *Neuroimaging Clinics of North America*, 12, 325-338. doi:10.1016/S1052-5149(02)00004-7
28. Mittl, R.L., Grossman, R.I., Hiehle, J.F., Hurst, R.W., Kauder, D.R., Gennarelli, T.A., et al. (1994) Prevalence of MR evidence of diffuse axonal injury in patients with mild head injury and normal head CT findings. *American Journal of Neuroradiology*, 15, 1583-1589.
29. Gejjerstam, J.L., Ordsson, S. and Britton, M. (2006) Octopus study investigators. Medical outcome after immediate computerized tomography or admission for observation in patients with mild head injury: Randomize controlled trail. *BMJ*, 333, 465. doi:10.1136/bmj.38918.669317.4F
30. Youmans, J.R. (1982) *Neurological surgery*. Saunders, Philadelphia.
31. Swischuk, L.E. (1997) *Imaging of the newborn, infant, and young child*. 4th Edition, Lippincott Williams & Wilkins.
32. Armstrong, P. and Wastie, M.L. (2001) *A concise textbook of radiology*. Arnold.